

CAOS 2014 Paper Submission

A Patient-Specific Measurement Technique to Model the Kinematics of the Shoulder in Tennis Players

C. Charbonnier¹, S. Chagué¹, F.C Kolo², A. Lädermann³

¹Medical Research Department, Artanim Foundation, Geneva, Switzerland

²Rive Droite Radiology Center, Geneva, Switzerland

³Division of Orthopaedics and Trauma Surgery, La Tour Hospital, Meyrin, Switzerland and Faculty of Medicine, University of Geneva, Geneva, Switzerland

Introduction

Instability and impingement of the shoulder are commonly described causes of shoulder pain in the overhead athlete, particularly in tennis players (prevalence of 50% for middle-aged players). During tennis movements, several impingements could occur: subcoracoid [1] and anterosuperior [2] impingements at the follow-through phase of forehand and the backhand preparation phase; subacromial [3] and posterolateral [4] impingements at the cocking phase of serve when the arm is in extreme abduction and external rotation. The precise causes for these impingements remain unclear, but it is believed that repetitive contact, glenohumeral instability, scapular orientation, etc., may play a role in the development of symptomatic impingement.

To our knowledge, impingement and glenohumeral instability at critical tennis positions have never been dynamically evaluated in-vivo. To this end, measuring and modeling the dynamic shoulder kinematics is required, but remains a challenging task in the biomechanical field. Optical motion capture systems offer good solutions to non-invasively record dynamic and large ranges of motion (ROM). However, drawbacks are related to soft tissue artifacts (STA) affecting kinematic estimation, in particular precise joint translations that are crucial to assess glenohumeral stability.

The purpose of this study was to develop a patient-specific measurement technique based on motion capture and Magnetic Resonance Imaging (MRI) to accurately determine glenohumeral kinematics (rotations and translations). The second objective was to evaluate through computer simulations impingements and stability during tennis movements.

Methods

MR arthrography and motion capture of the shoulder were carried out in 10 tennis players (9♂, 1♀, mean age: 39.7 ± 8.9 years). Based on the MR images, patient-specific 3D models of the shoulder bones were reconstructed and local coordinates systems established [5] (Fig. 1a). Motion data from the subjects were recorded during tennis movements (3 trials per shot). Glenohumeral kinematics was computed from the markers trajectories using a global optimization algorithm (to minimize STA errors globally) with loose constraints on joint translations. Joint translations were thus permitted but limited. Accuracy of the model for glenohumeral orientation was within 4° for each anatomical plane and within 3 mm for glenohumeral translations. Although the translation errors were significant, the results showed that the translations patterns computed with the model were in good agreement with previous works [6]. The resulting computed motions were applied to the tennis player's shoulder 3D models reconstructed from their MRI data (Fig. 1b).

While visualizing the shoulder joint in motion, minimum humero-acromial, humero-coracoid and humero-glenoid distances that are typically used for the diagnosis of impingements were measured at the critical tennis positions (Fig. 1c). Given the thickness of the potential impinged tissues, impingement was considered when the computed distance was < 5 mm (< 6 mm for the humero-acromial distance).

During serve, glenohumeral stability was assessed at the cocking, deceleration and finish phases which are known to be the more demanding in terms of inertia and ROM. Glenohumeral translation was defined as the anterior-posterior and superior-inferior motion of the humeral head center relative to a glenoid coordinate system. Subluxation was defined as the ratio (in %) between the translation of the humeral head center and the radius of the width (anteroposterior subluxation) or height (superoinferior subluxation) of the glenoid surface. Instability was thus considered when the subluxation was $> 50\%$, which corresponds to a loss of congruence superior to half the radius of the width (or height) of the glenoid.

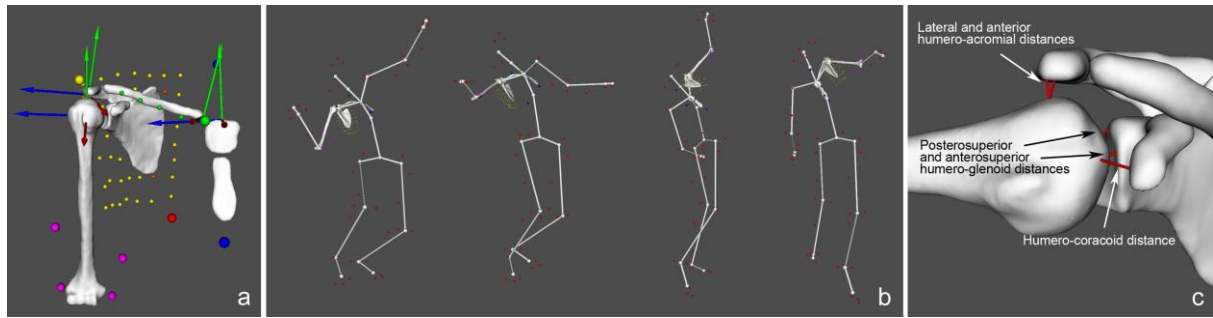


Fig. 1: a) 3D reconstruction showing the bone coordinate systems and the markers setup (small colored spheres); b) Kinematic animation of the shoulder during serve; c) Visualization of the humero-acromial, humero-coracoid and humero-glenoid distances during motion. The red lines represent the minimum distances.

Results

No subcoracoid impingement was detected. Anterosuperior impingements were observed in 2 subjects (29% of the trials) during forehand. Anterior and lateral subacromial impingements occurred during the cocking phase of serve in 3 (29% of the trials) and 4 subjects (42% of the trials), respectively. Posterosuperior impingements during the cocking phase of serve were the most frequent (7 subjects, 75% of the trials). In this position, glenohumeral translation was anterior (mean: 34%) and superior (mean: 13%). During the deceleration phase of serve, anterior and superior translation varied between 8-57% and between 5-34%, respectively. During the finish phase, anterior translation was slightly more intense (mean: 44%), while superior translation remained low (mean: 1%). MR images revealed eleven rotator cuff lesions in five subjects, and six labral lesions in five subjects (two inferior, two posterior and two posterosuperior), which were relevant with respect to the detected impingements.

Conclusion

Thanks to this patient-specific measurement technique, shoulder impingement and stability were actively assessed and demonstrated in-vivo during tennis movements. Posterosuperior impingement was frequent when serving. No instability could be noted in this population. Tennis players presented frequent radiographic signs of structural lesions which seem to be mainly related to posterosuperior impingement due to repetitive abnormal motion contacts [4]. Our findings are consistent with this hypothesis. To our knowledge, this is the first study demonstrating that a dynamic and precise motion analysis of the shoulder is feasible using an external measurement system, such as motion capture. This original method may open new horizons and could be further generalized to other shoulder pathologies and sports.

References

- [1] Gerber C, Terrier F, Ganz R. The role of the coracoid process in the chronic impingement syndrome. *JBJS Am*, 67:703-708, 1985.
- [2] Gerber C, Sebesta A. Impingement of the deep surface of the subscapularis tendon and the reflection pulley on the anterosuperior glenoid rim: a preliminary report. *J Shoulder Elbow Surg* 9:483-490, 2000.
- [3] Neer C. Anterior acromioplasty for chronic impingement syndrome in the shoulder: a preliminary report. *JBJS Am*, 54:41-50, 1972.
- [4] Walch G, Boileau P, Noel E, Donell S. Impingement of the deep surface of the supraspinatus tendon on the posterior glenoid rim: an arthroscopic study. *J Shoulder Elbow Surg*, 1:238-245, 1992.
- [5] Wu G, van der Helm F, Veeger H, Makhsouse M, Royf PV, et al. ISB recommendation on definitions of joint coordinate systems of various joints for the reporting of human joint motion - part II: shoulder, elbow, wrist and hand. *J Biomech*, 38:981-992, 2005.
- [6] Matsuki K, Matsuki K, Yamaguchi S, Ochiai N, Sasho T, et al.. Dynamic in vivo glenohumeral kinematics during scapular plane abduction in healthy shoulders. *J Orthop Sports Phys Ther*, 42(2):96-104, 2012.